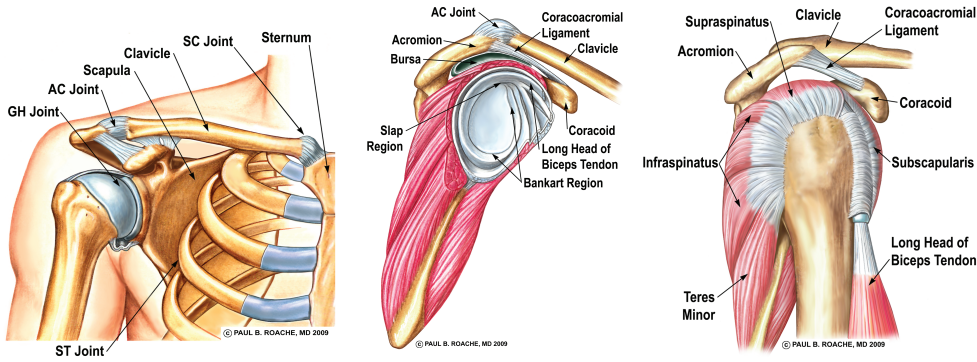
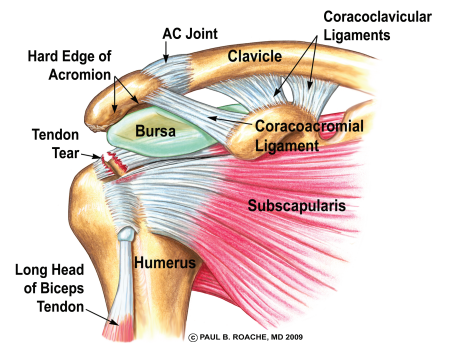
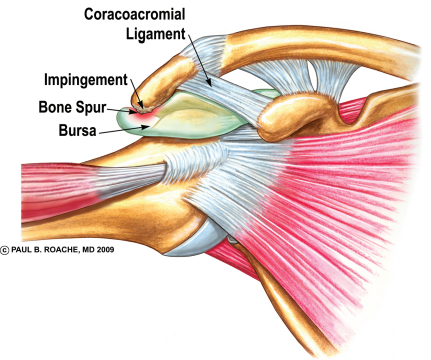


Common Shoulder Injuries

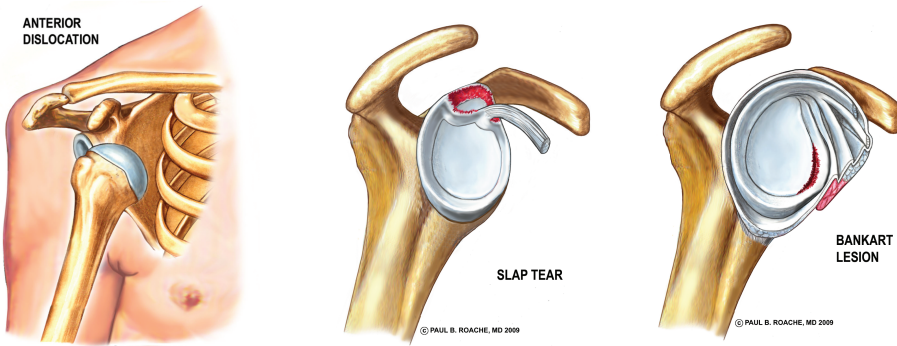Anatomy: The Ball-and-Socket



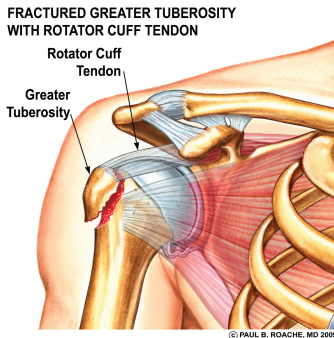
Rotator Cuff Injuries: Impingement, Inflammation and Tendon Tears



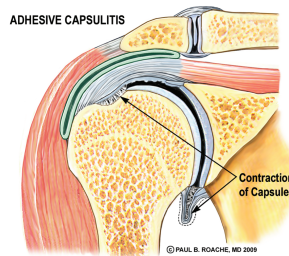
Labral Injuries: Dislocations and SLAP Tears



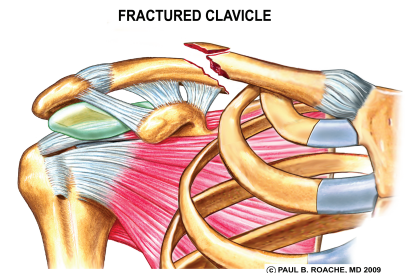
Fractures of the Ball (Proximal Humerus)



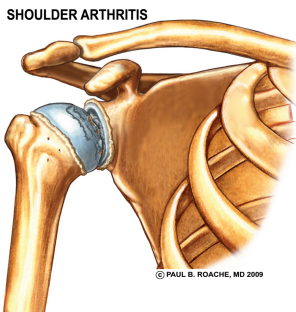
Frozen Shoulder



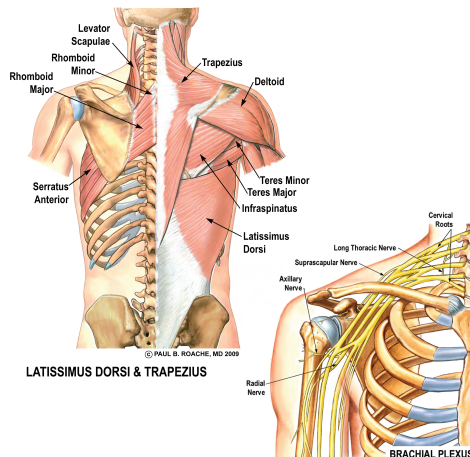
Clavicle Fractures and AC Joint injuries



Cartilage Injuries: Arthritis of the Ball-and-Socket



Neck and Nerve injuries



GRADE 3 INJURY

